

IVERIC  
BIO

DEVELOPING TRANSFORMATIVE  
THERAPIES  
FOR RETINAL DISEASES

---

February 2022  
NASDAQ: ISEE

# Forward-looking statements

Any statements in this presentation about IVERIC bio (the Company)'s future expectations, plans and prospects constitute forward-looking statements for purposes of the safe harbor provisions under the Private Securities Litigation Reform Act of 1995. Forward-looking statements include statements about the strategy, operations and future expectations and plans and prospects for the Company, and any other statements containing the words “anticipate,” “believe,” “estimate,” “expect,” “intend”, “goal,” “may”, “might,” “plan,” “predict,” “project,” “seek,” “target,” “potential,” “will,” “would,” “could,” “should,” “continue,” and similar expressions.

In this presentation, the Company's forward looking statements include statements about the results of clinical trials and the potential utility of Zimura (avacincaptad pegol or ACP). Such forward-looking statements involve substantial risks and uncertainties that could cause the Company's research and development programs, future results, performance or achievements to differ significantly from those expressed or implied by the forward-looking statements. Such risks and uncertainties include, among others, the timing and progress of clinical trials and other research and development programs, and other factors discussed in the “Risk Factors” section contained in the quarterly and annual reports that the Company files with the Securities and Exchange Commission.

Any forward-looking statements represent the Company's views only as of the date of this presentation. The Company anticipates that subsequent events and developments may cause its views to change. While the Company may elect to update these forward-looking statements at some point in the future, the Company specifically disclaims any obligation to do so except as required by law.

# EVALUATION OF GA GROWTH PARAMETERS AND IMPACT ON FOVEAL PROGRESSION: POST HOC ANALYSIS OF THE GATHER1 TRIAL

---

Glenn J Jaffe, MD<sup>1</sup>

Zane Zemborain, BS<sup>1</sup>

Sina Farsiu PhD<sup>1</sup>

Dhaval Desai, PharmD<sup>2</sup>

Liansheng Zhu, PhD<sup>2</sup>

Angiogenesis, Exudation, and Degeneration – Virtual Edition

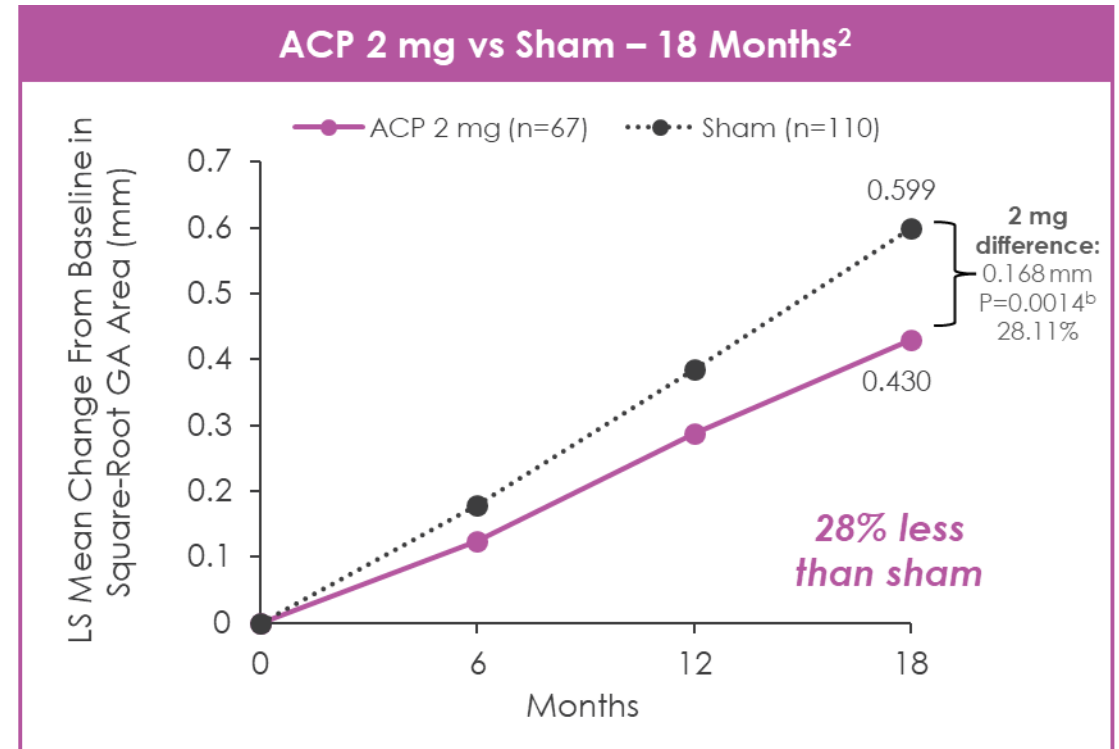
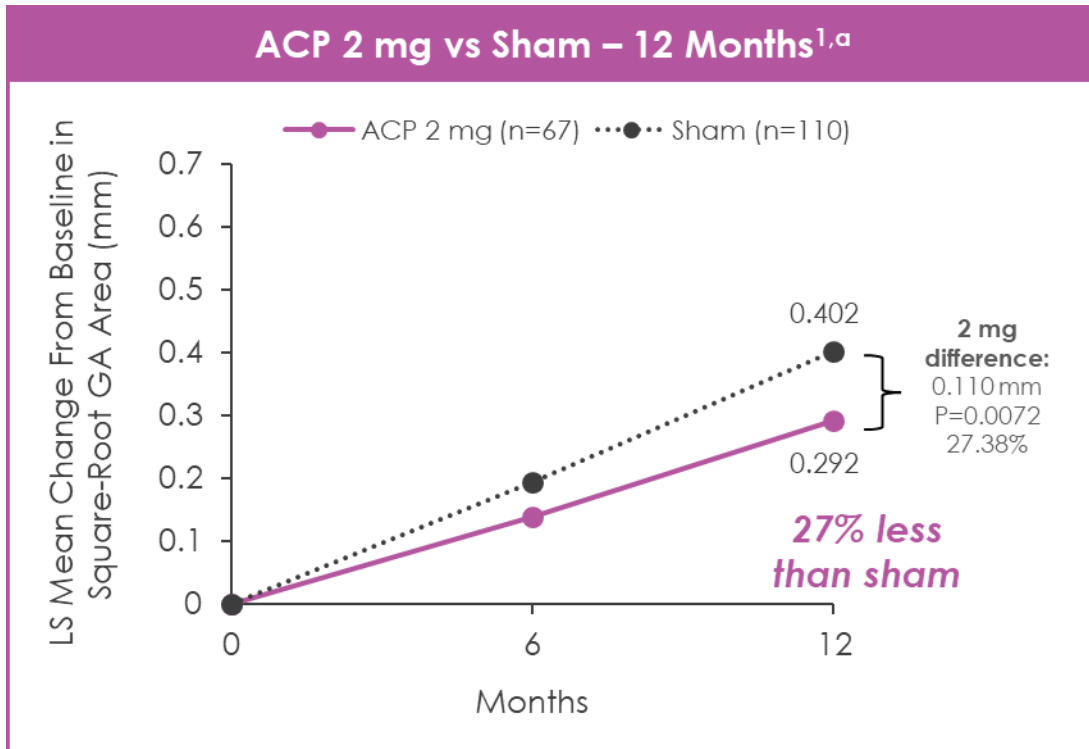
February 11-12, 2022

# Financial disclosures

- Roche
- Iveric
- Novartis
- EyePoint
- Annexon

- **Post hoc analysis included a subset of eyes with Heidelberg FAF and OCT images from GATHER1**
- **Slower lesion growth at 18 months was observed in patients receiving ACP 2 mg as compared to patients receiving sham in 5 standardized regions surrounding and including the central foveal area, consistent with natural history**
- **Impact of central foveal area preservation requires further long-term studies**

- Prospective, randomized, double-masked, Phase 3 trial comparing ACP to sham in patients with GA secondary to AMD



Note: Based on LS means from MRM model; ITT population Hochberg procedure was used for significance testing; prespecified and descriptive analysis. These LS means are estimates of the MRM model, drawing on all available data, including data from groups with different randomization ratios in Part 1 and Part 2, and should not be interpreted as directly observed data.

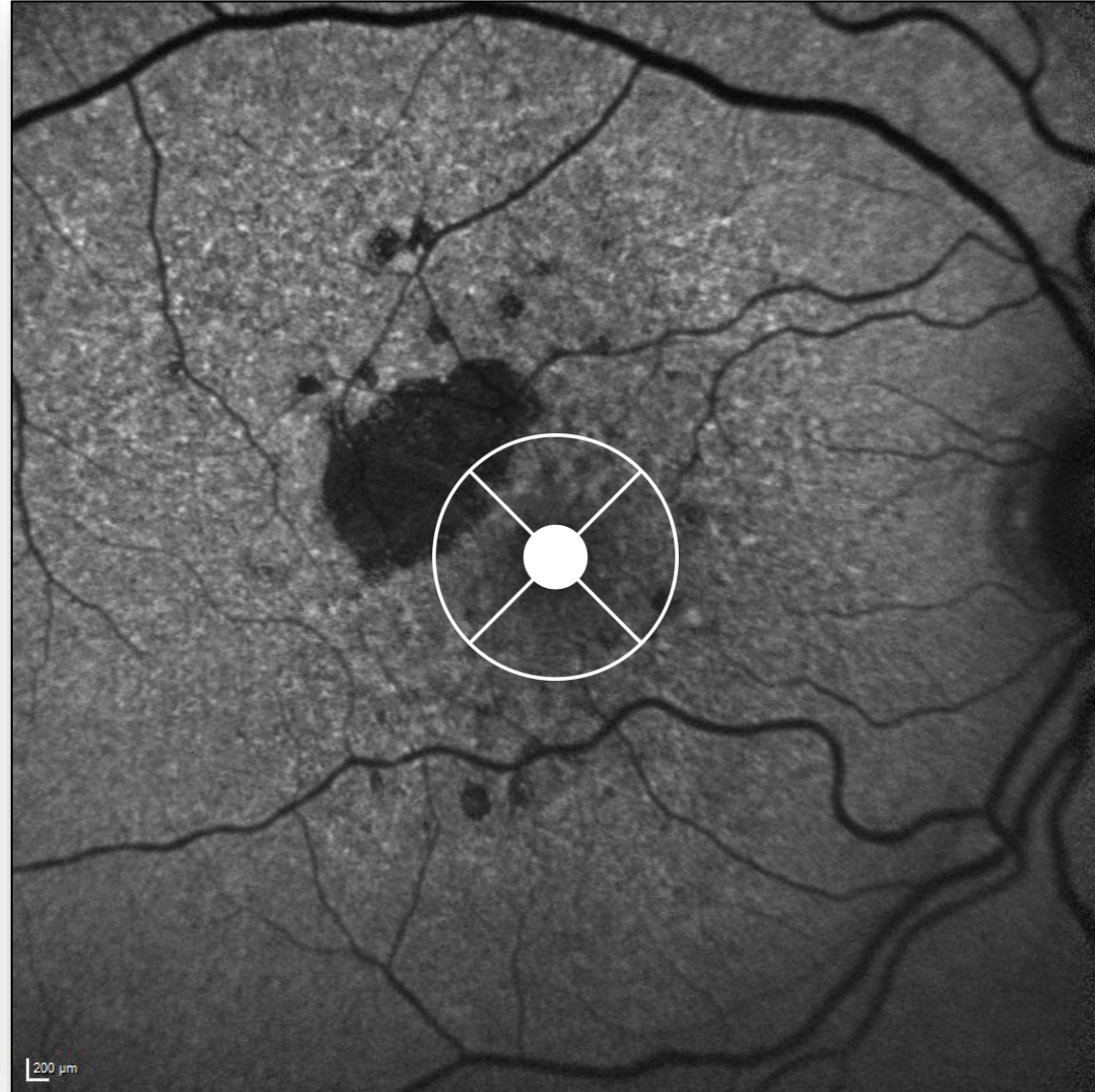
<sup>a</sup>Primary endpoint.

<sup>b</sup>18-month P values are descriptive in nature.

ACP, avacincaptad pegol; AMD, age-related macular degeneration; GA, geographic atrophy; ITT, intent-to-treat; LS, least square; MRM, mixed-regression model.

1. Jaffe GJ, et al. *Ophthalmology*. 2021;128(4):576-586. 2. Data on file. Iveric Bio.

# Natural history of GA progression

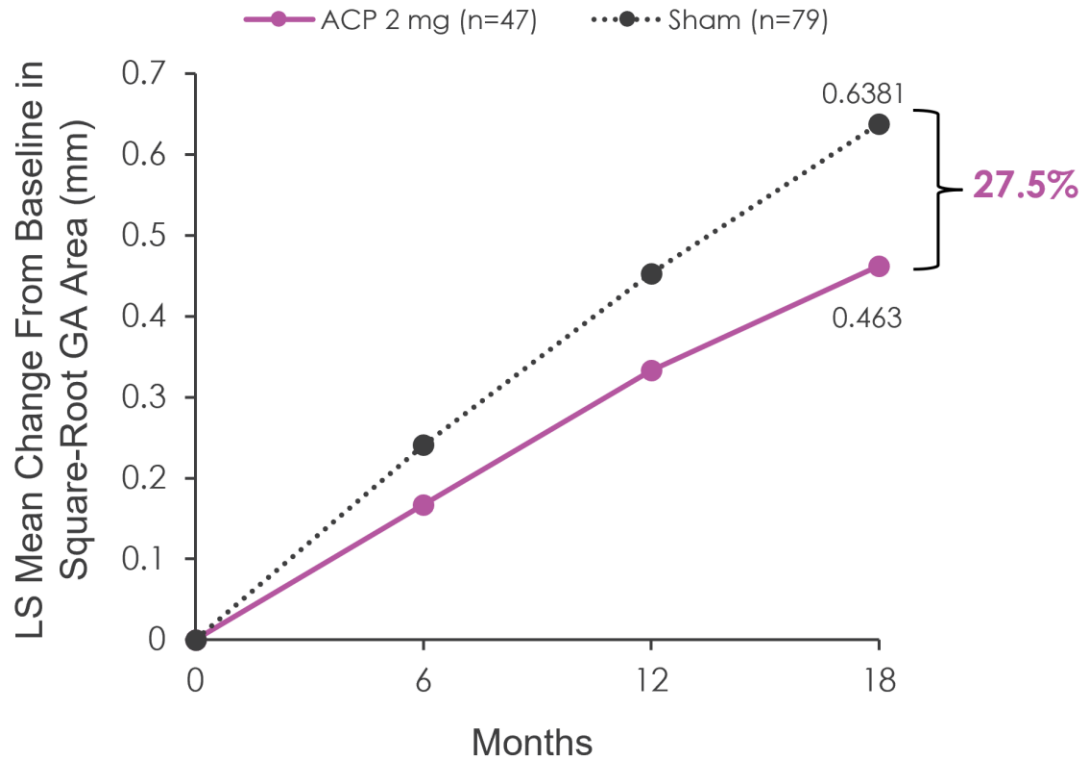


Courtesy:  
Frank Holz, MD

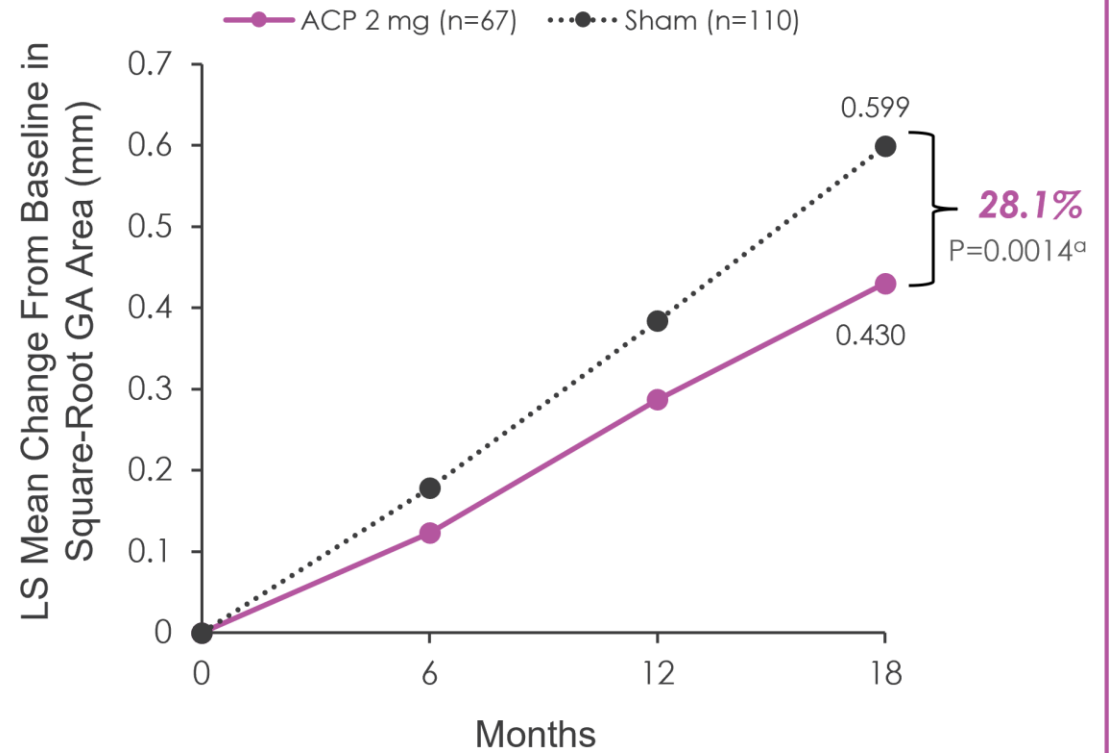
Region-dependent effect on GA lesion growth

- Study eyes with Heidelberg FAF and OCT at selected visits
  - 47 ACP 2 mg eyes
  - 79 sham eyes

## Post hoc Analyses Results

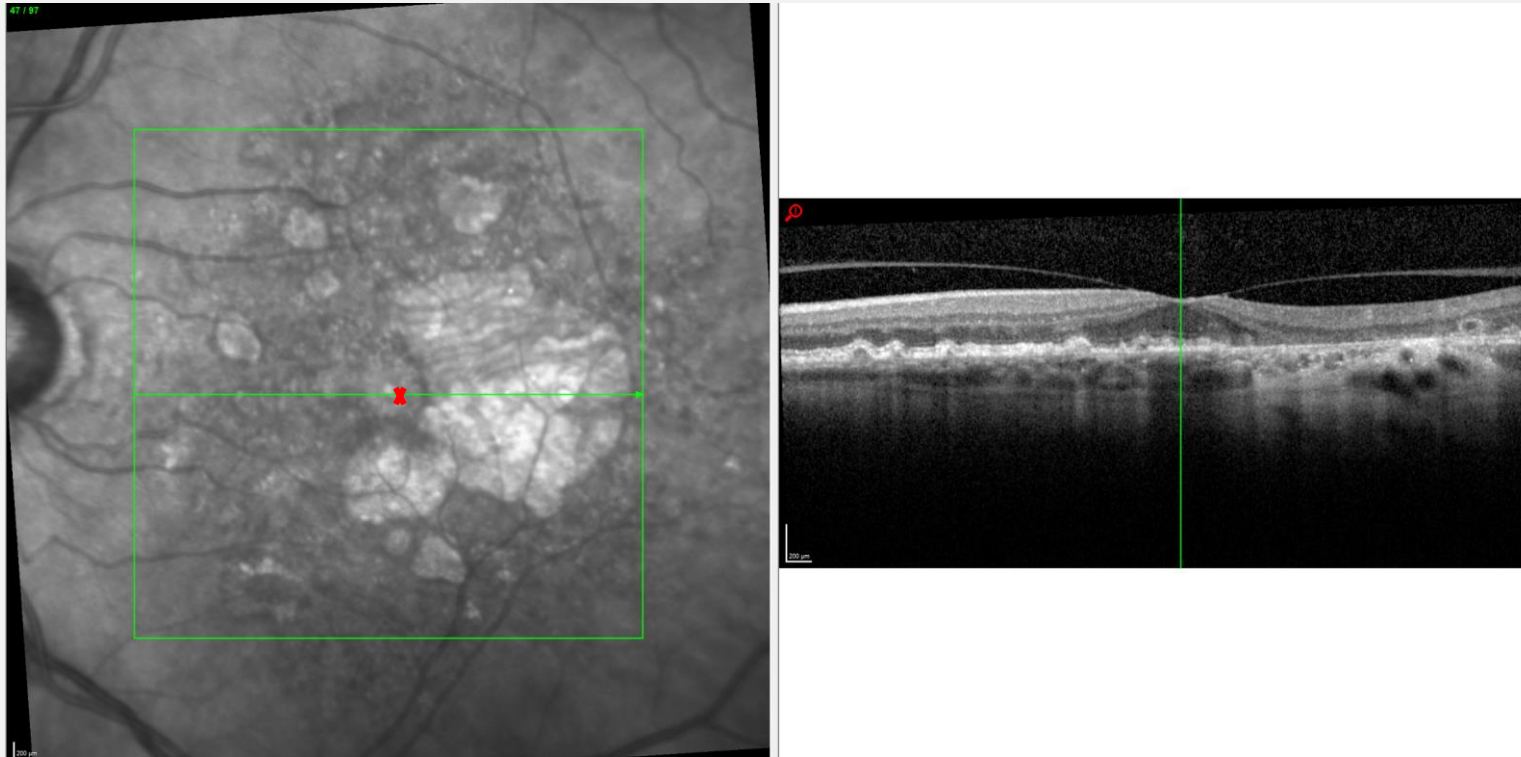


## GATHER1 Study Results



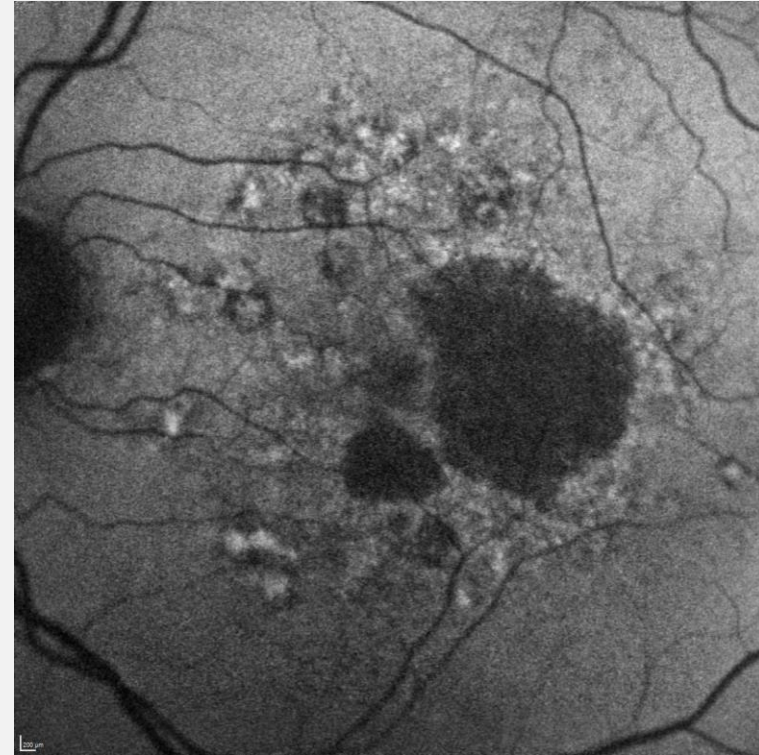
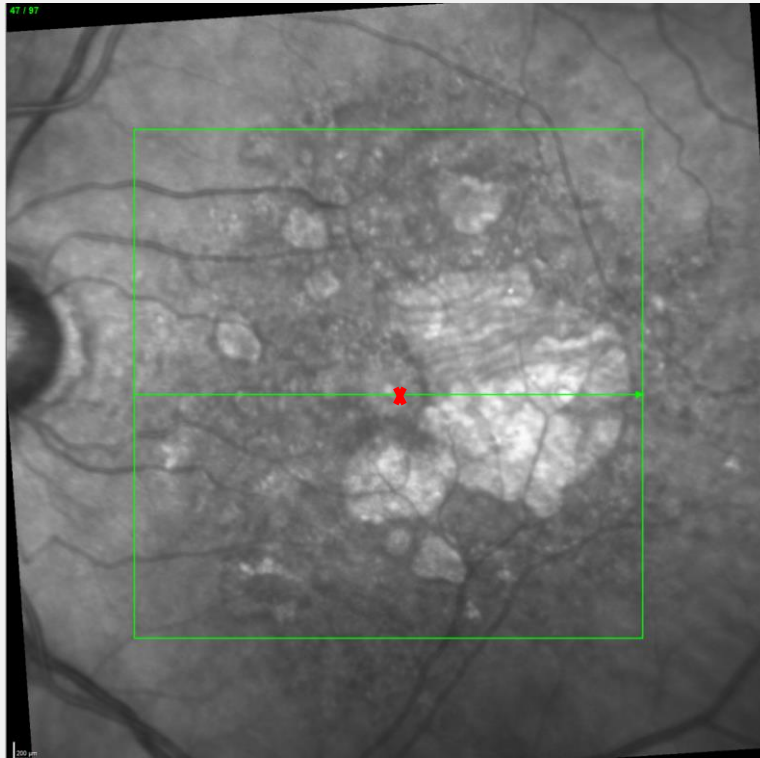
<sup>a</sup>18-month P values are descriptive in nature.  
ACP, avacincaptad pegol; GA, geographic atrophy; ITT, Intent-to-treat; LS, least square.  
Data on file. Iveric Bio.

# Centerpoint is identified on OCT and IR image

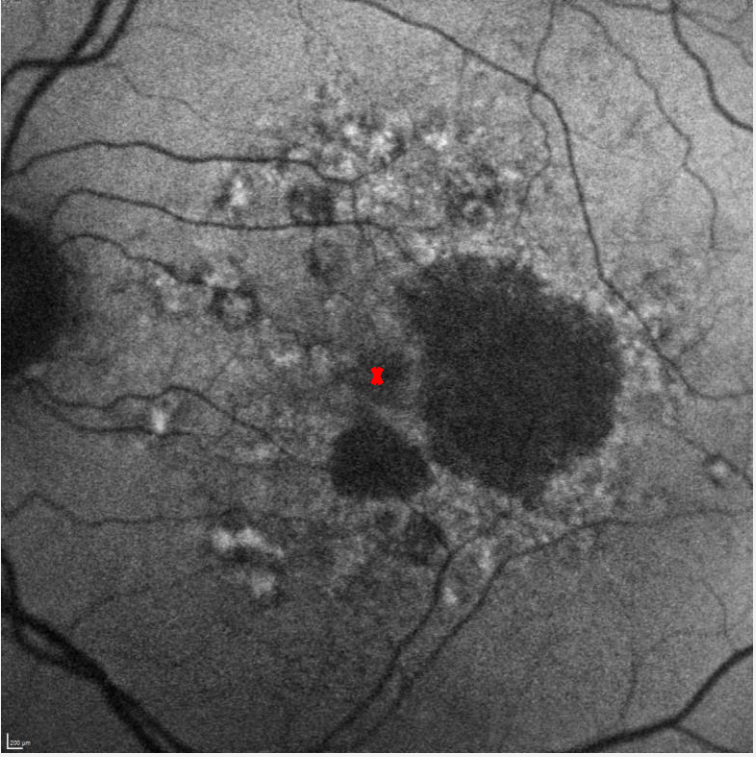
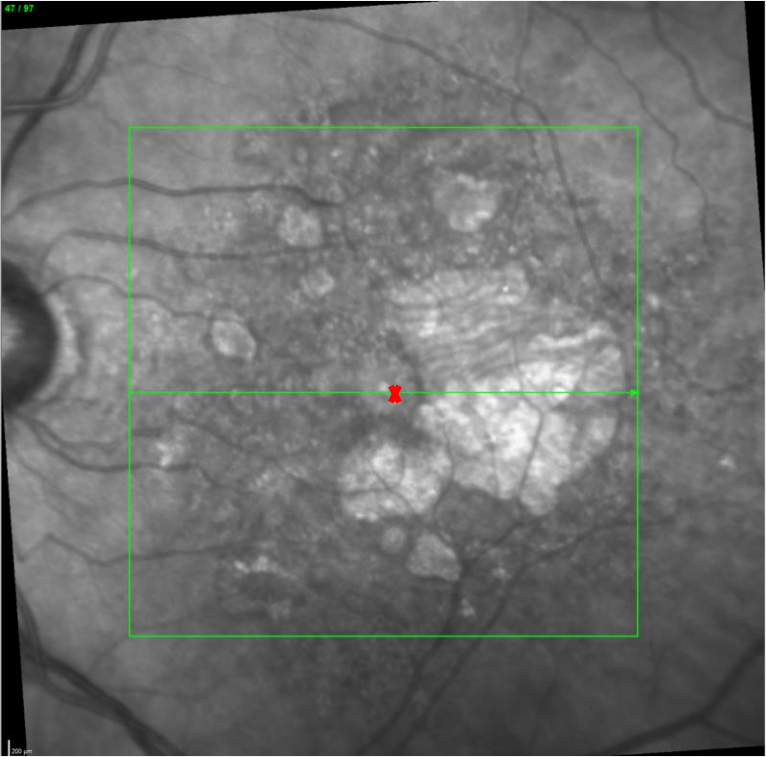


Vertical green line on OCT B-scan (right image) is seen as short hash mark on IR image (red X)

# IR image registered to FAF image



# Centerpoint registered from IR to FAF image



# GA area segmented in Region Finder

**SPECTRALIS® RegionFinder**  
Single Exam Report

Patient: ISEE2008, 061-80127      DOB: 1/1/2001      Sex: M      **OS**  
Patient ID: 061-80127      Exam.: 9/22/2020      Comment:  
Diagnosis:


BluePeak, Total sensitivity 107

**Reading Details**

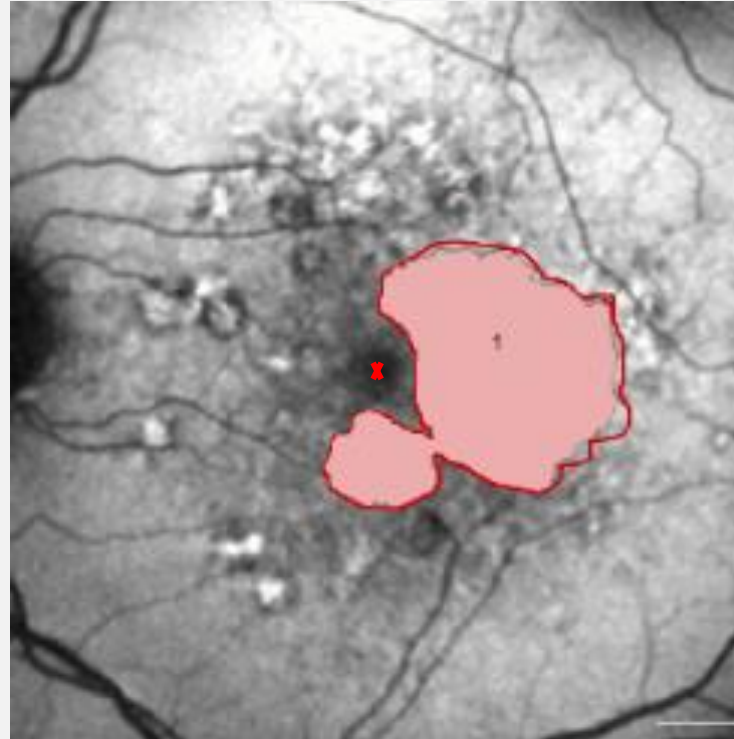
Date: 9/24/2020      Number of regions: 1  
Time: 07:22:23      Perilesional pattern: unseeded  
Total region size: 6.518 mm<sup>2</sup>

N°	Region Color	Size [mm <sup>2</sup> ]	Growth Power [%]	Growth Limit [%]	Min-Max Vessel [µm]	Strap Ratio
1	■	6.518	62	100	30 - 30	0.00

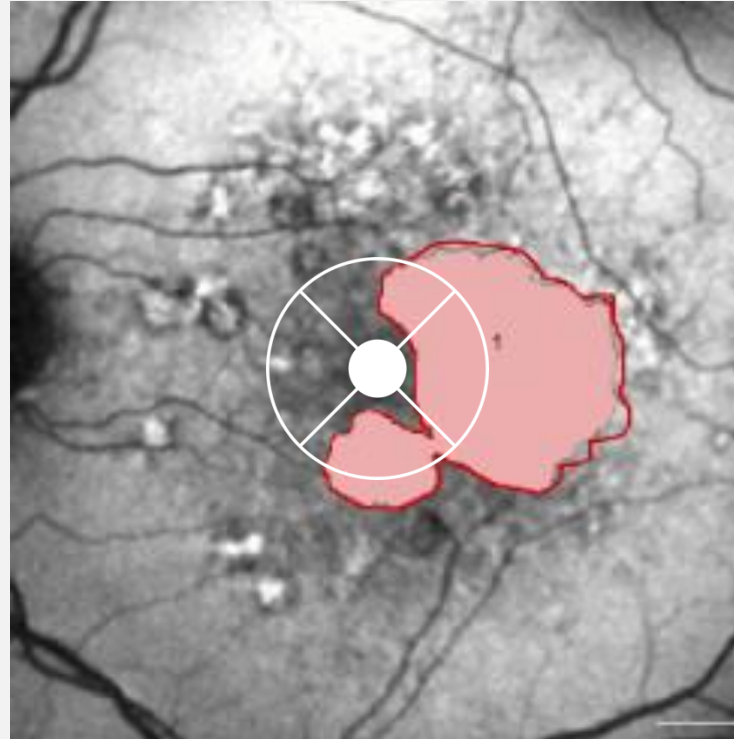
# GA regions are exported and saved



# GA region overlaid on FAF image with marked centerpoint



# GA region overlaid on FAF image with marked centerpoint

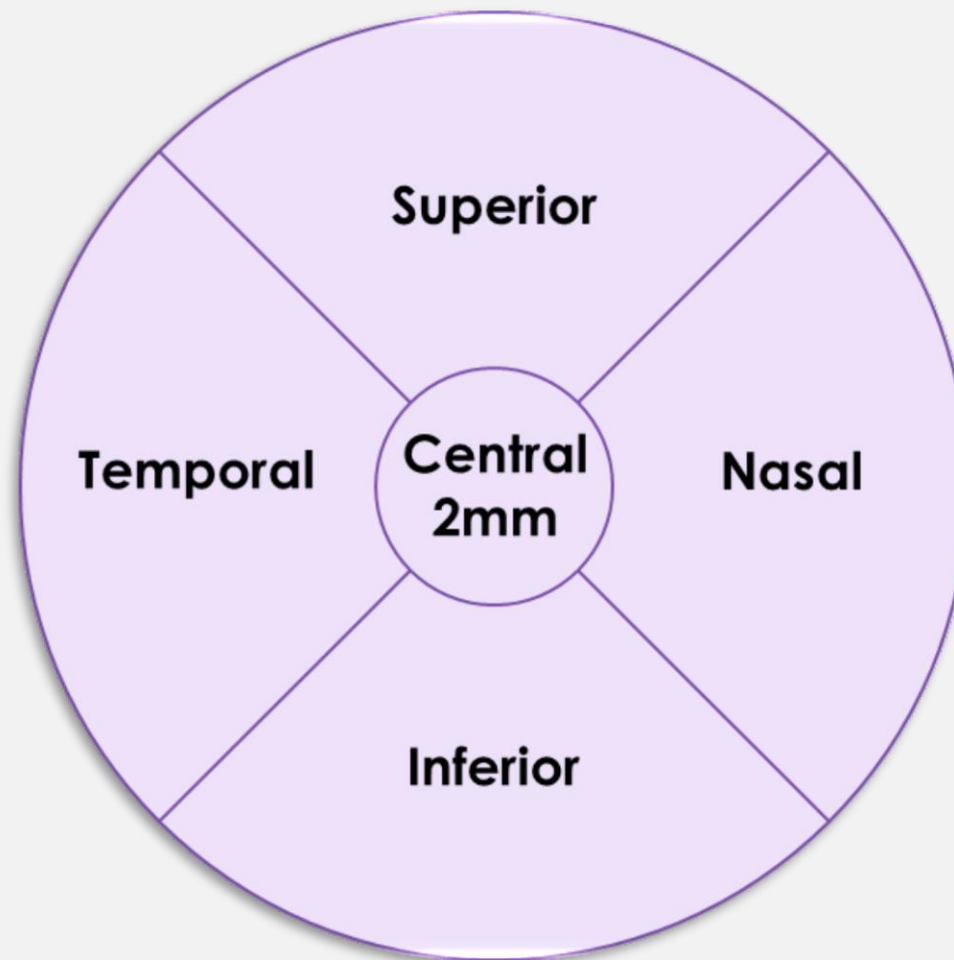


## Central Foveal Region:


- 2 mm diameter circle

## Non-Central Region:

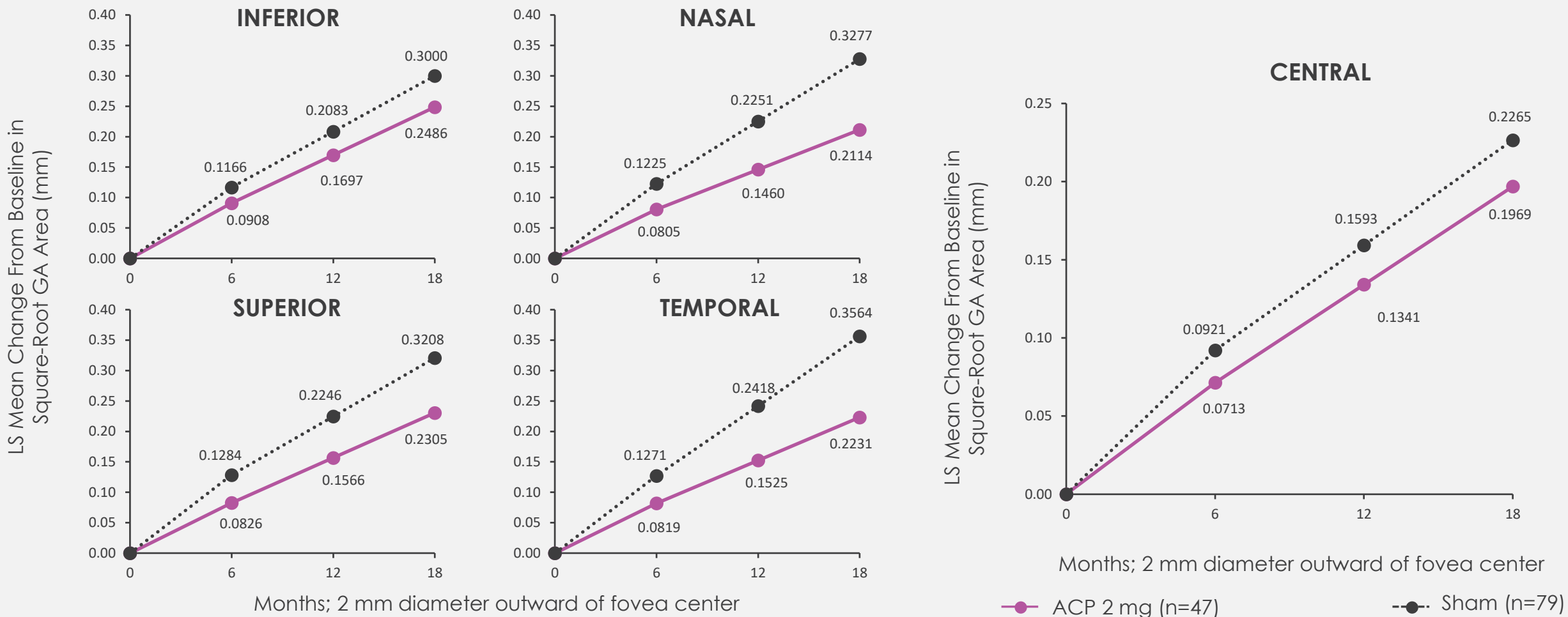
- 2-8 mm: Superior/Inferior/Temporal/Nasal



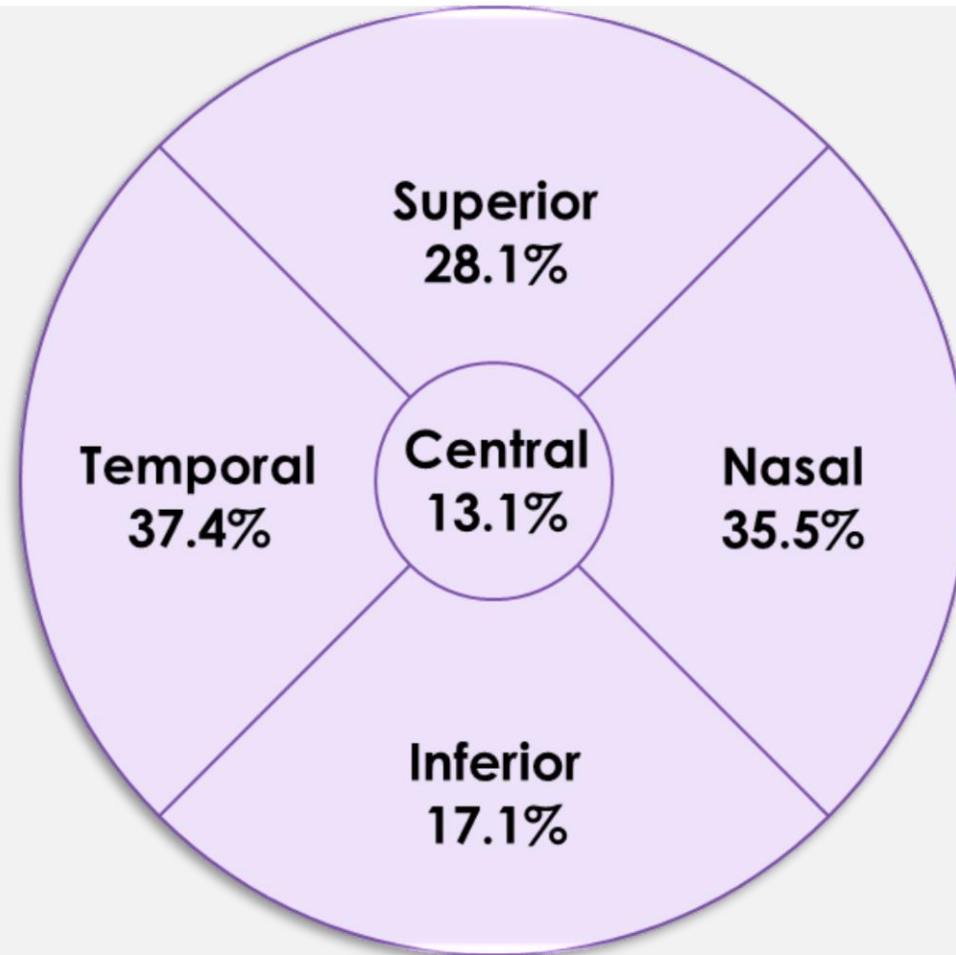
# Results



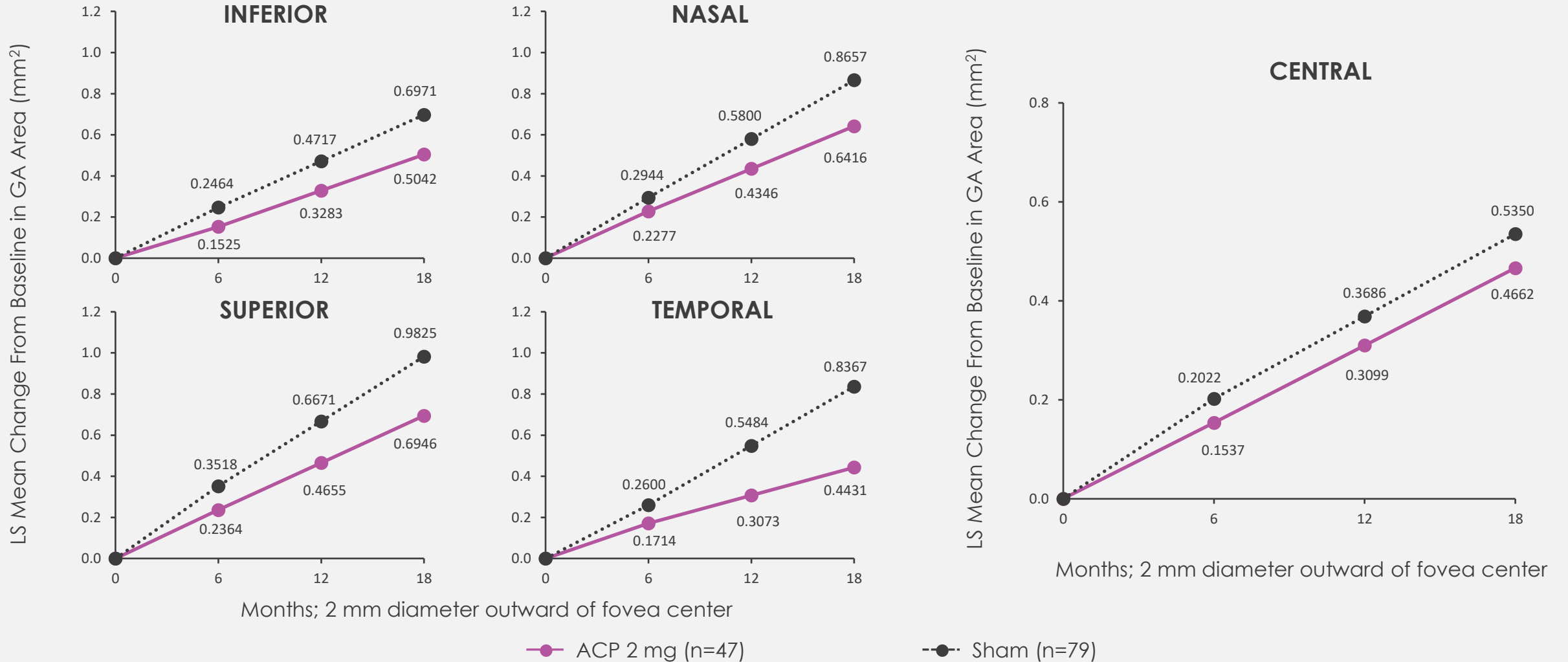
# Decrease in GA growth observed with ACP 2 mg vs sham at all locations and in line with natural history, square-root transformed (mm)



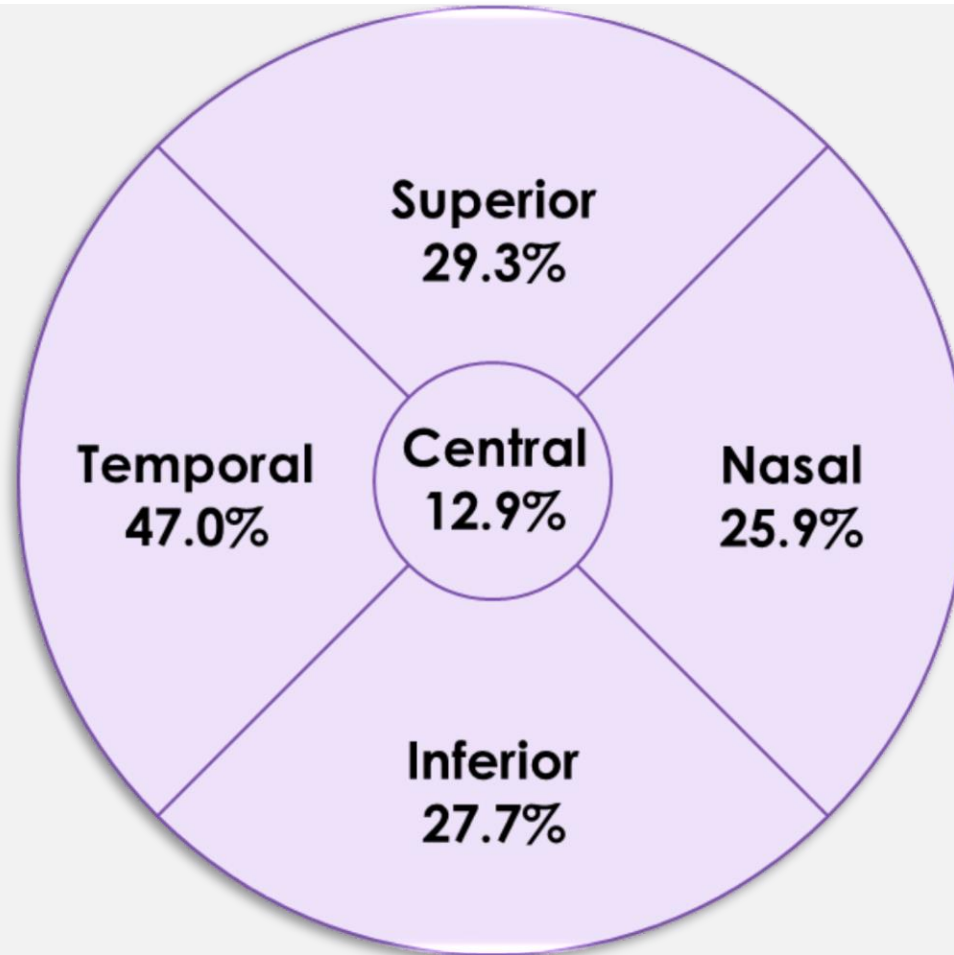
Decrease in GA growth observed with ACP 2 mg vs sham at all locations and in line with natural history, square-root transformed (mm)



# Decrease in GA growth observed with ACP 2 mg vs sham at all locations and in line with natural history, non-transformed (mm<sup>2</sup>)



Decrease in GA growth observed with ACP 2 mg vs sham at all locations and in line with natural history, non-transformed (mm<sup>2</sup>)



- **Post hoc analysis included a subset of eyes with Heidelberg FAF and OCT images from GATHER1**
- **Slower lesion growth at 18 months was observed in patients receiving ACP 2 mg as compared to patients receiving sham in 5 standardized regions surrounding and including the central foveal area, consistent with natural history**
- **Impact of central foveal area preservation requires further long-term studies**

# THANK YOU!

GATHER1 INVESTIGATORS

DUKE READING CENTER TEAM

